


NEWS FROM THE NZOA KNEE SOCIETY

ACC Knee Consideration Factors & Southern Cross.

The Knee Society and ACC ratified these late last year. Please look over these in detail and apply these factors to your ARTP. We have discussed these consideration factors with Southern Cross. If a patient does not reach the criteria for ACC funded surgery Southern Cross will not require the patient to be declined by ACC. Make sure you detail this in your clinical letter.

ACC Knee Surgery Entitlement

ACC and NZOA Knee Society Consideration Factors (July 2012)



Factors for consideration in traumatic internal derangement of the knee

ACC funding of elective surgery is considered on a case-by-case basis and is based on the ARTP and information ACC collects on the case from a variety of sources. The following consideration factors have been developed by ACC in conjunction with the NZOA Knee Society.

General Factors

The principal factors in assessment of a request for knee surgery are:

1. An ACC-covered injury to the knee (which is a prerequisite)
2. Previous problems in the injured knee and their relevance
3. An incident with the acute onset of pain and dysfunction
4. Clinical examination signs
5. Investigations
6. Patient demographics

Additional factors

Meniscal pathology

Important considerations relating to meniscal pathology include findings of moderate to advanced osteoarthritis on weight bearing X-rays and/or MRI scan.

Traumatic meniscal tears may occur in the presence of osteoarthritis. Factors to consider include:

1. The history and mechanism of incident and the degree and type of force involved. A torsional force with an axial load is considered an appropriate mechanism.
2. Mechanical symptoms - Many clinical findings on examination will be similar in an osteoarthritic knee to those in a knee with a meniscal tear. An exception to this general similarity would be genuine mechanical locking of the stressed knee.
3. X-ray findings (Weight bearing X-rays mandatory) – Signs to be considered on X-ray include the loss of joint space in the affected compartment. On a weight bearing film Kellgren-Lawrence Grade 3 change would be indicative of, at the very least, moderate osteoarthritis. The size of osteophytes is not of itself predictive.
4. MRI features in keeping with severe osteoarthritis include:
 - a. Areas of full thickness articular cartilage loss; and/or
 - b. Bone marrow oedema; and/or
 - c. An extruded meniscus (not to be confused with a displaced flap tear).

NB. The configuration of a meniscal tear may not, in itself, be indicative of causation. The degree of associated osteoarthritic change (if any) should be considered, and is likely to be more relevant.

5. In general, after surgical treatment of a meniscal tear, the traumatic component of the injury should have resolved by 3 months. Ongoing symptoms after this time are probably due to other non-traumatic factors and ACC should assess further entitlements (e.g. further arthroscopy, high tibial osteotomy and any form of joint replacement) against that general observation.

Osteoarthritis

Additional factors for consideration of ACC funding of a high tibial osteotomy, total knee joint replacement (TKJR) or knee arthroplasty request include:

1. Prior meniscectomy for a traumatic meniscal tear, without degenerative articular cartilage at the time of the index procedure
2. Prior cruciate or multi-ligament injury
3. Traumatic full thickness isolated chondral lesion
4. Intra articular knee fracture
5. Mal-union of previous lower limb fracture

Patellofemoral instability

Additional factors for determination of ACC funding of elective surgery requests to address patellofemoral instability include:

1. The history and mechanism of incident and the degree and type of force involved. A history of the need for relocation indicates a significant traumatic event.
2. A history of instability or recurrent subluxation/ dislocation on the opposite knee. The presence of generalised ligamentous laxity.
3. Patient demographics.
4. The clinical signs:
 - a. Tenderness over the medial retinaculum.
 - b. The presence of a haemarthrosis.
 - c. The results of a patella apprehension test (compared with findings at the opposite knee).
5. The radiographic signs:
 - a. A bony avulsion off the medial facet of the patella (indicative of MPFL avulsion).
 - b. An osteochondral fracture or loose body arising from the medial facet of the patella and/or the lateral condyle of the femur.
 - c. Bone marrow oedema on an MRI scan seen on the medial facet of the patella and/or lateral femoral condyle. The timing of the MRI scan needs to be considered
 - d. MRI evidence of disruption of the medial retinaculum (MPFL).

Note: The minimum radiological requirement for an Assessment Report & Treatment Plan (ARTP) when requesting ACC funding for elective surgery to address patellofemoral instability includes X-rays with the following views: AP weight bearing, lateral and skyline patella.

6. The presence of any of the following constitutional factors:
 - a. Signs of trochlear dysplasia (Dejour classification on a good lateral x-ray preferred).
 - b. Patella alta (Blackburn-Peel ratio preferred) - X ray or MRI accurate

c. A laterally placed fibial tubercle in relation to the trochlear groove (TT-TG distance). Normal values for TT-TG are up to 15mm.
An MRI is preferred as other structures such as the medial retinaculum, articular cartilage and bone oedema can be evaluated; however a CT is satisfactory.

7. The nature of the surgical procedure(s) that have been requested:

- a. Removal of loose body.
- b. Medial patellofemoral ligament (MPFL) reconstruction/ Medial plication.
- c. Realignment procedure such as tibial tubercle transfer.
- d. Lateral release.
- e. Treatment of the chondral surfaces.
- f. Reattachment of osteochondral fragment.
- g. A combination of the above.

Fig 1 Trochlea Dysplasia

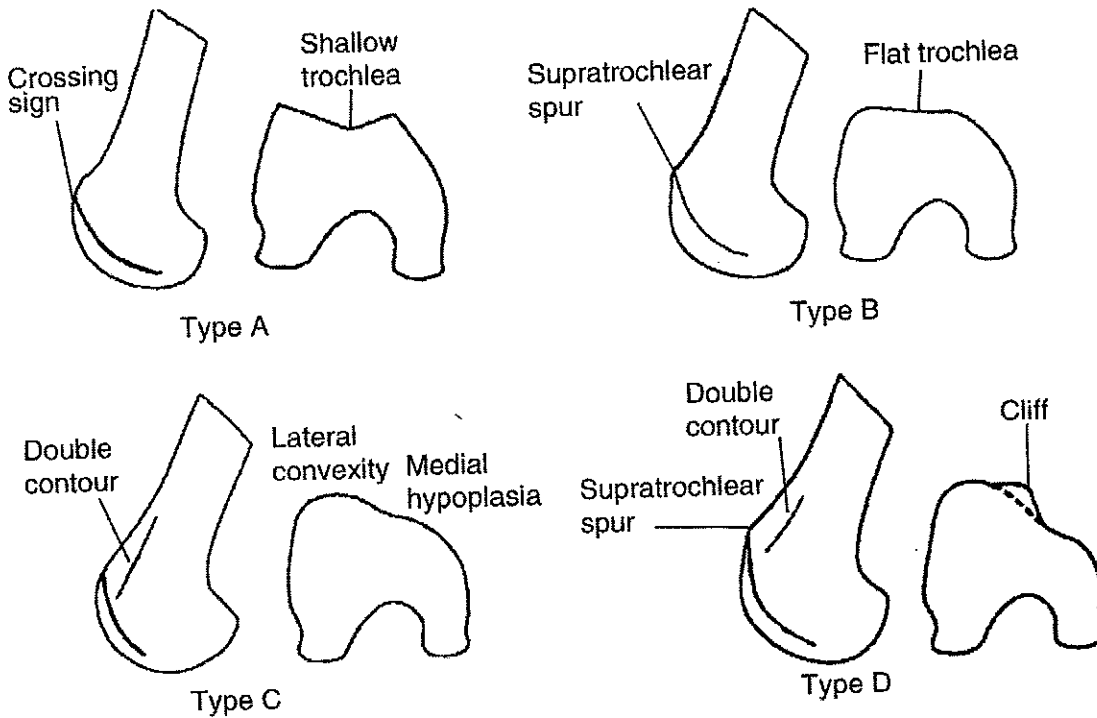


Figure 1

Classification of trochlear dysplasia.

A, Type A is characterized by the crossing sign on the lateral view (left) and by a shallow trochlea (sulcus angle $>145^\circ$) on the axial view (right).

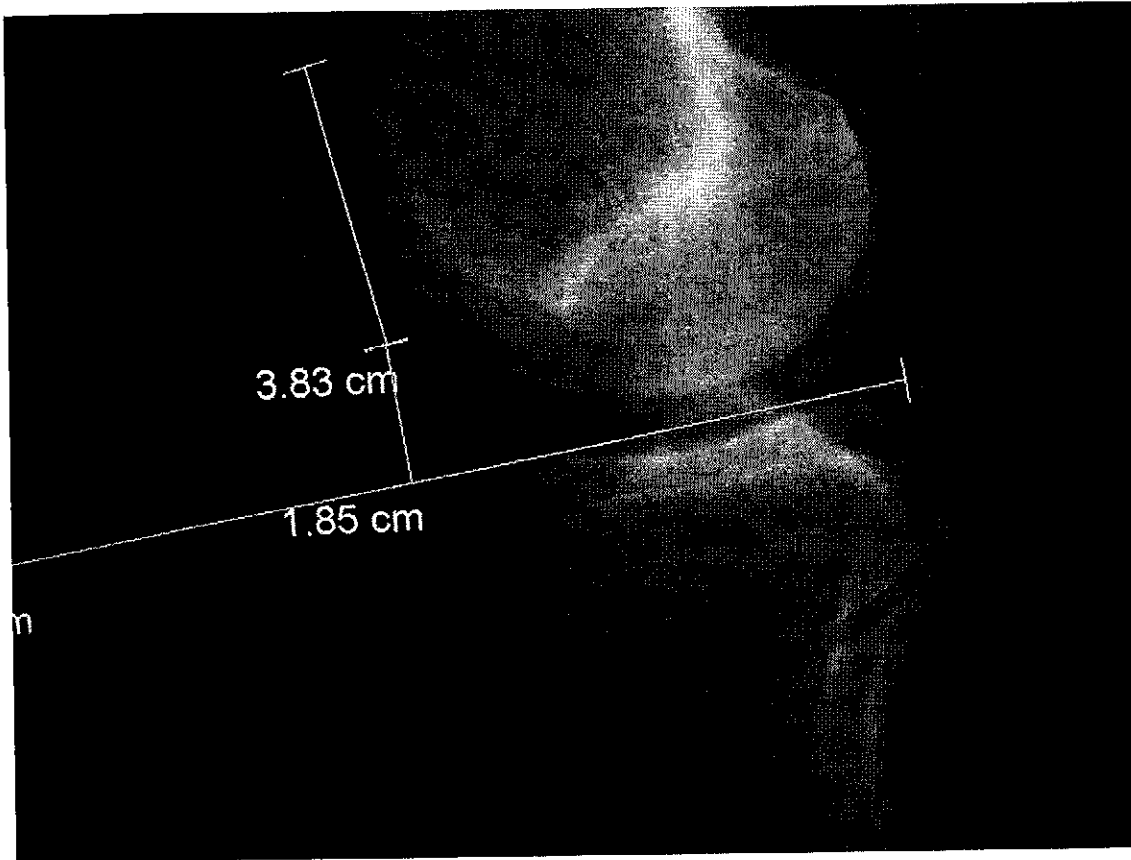
B, Type B is characterized by the crossing sign and supratrochlear prominence, or spur, on the lateral view (left) and by a flattened trochlea on the axial view (right).

C, In type C, the lateral view shows the crossing sign with double contour (left). On the axial view (right), the trochlea demonstrates lateral convexity and medial hypoplasia.

D, In type D, the crossing sign, double contour, and supratrochlear spur are seen on the lateral view (left), and asymmetry of the trochlear facets is seen on the axial view (right)

(Reproduced with permission from Dejour D, LeCoultrre B: Osteotomies in patello-femoral instabilities. *Sports Med Arthrosc* 2007;15:39-46.)

Fig 2 – Patella Alta – High riding patella; and its opposite abnormality, patella baja



The Blackburne-Peel index is calculated by measuring the perpendicular distance from the lower end of the articular surface of the patella to a line projected forward along the tibial plateau (the tibial plateau line) and then dividing that distance by the length of the articular surface of the patella. In this knee, the distance from the articular surface of the patella to the tibial plateau line is 1.85 cm and the length of the articular surface of the patella is 3.83 cm, indicating patella baja ($1.85 \text{ cm} \div 3.83 \text{ cm} = 0.48$ [normal range, 0.54 to 1.06]).